

# AN INTRODUCTION TO EQUINE METABOLIC SYNDROME AND EQUINE CUSHING'S DISEASE

Allison Doherty

Port Perry Veterinary Services



Me with my red-headed mares and their friend



# Equine Metabolic Syndrome

---



# What is it?

- Equine Metabolic Syndrome (EMS) is characterized by obesity or regional adiposity, laminitis, and insulin resistance
  - Insulin resistance occurs when the horse's tissues do not respond to insulin appropriately, causing insulin levels to rise
- Horses that are at risk include:
  - “Easy keepers”
  - Inadequate exercise
  - Graze lush pastures
  - Obese horses fed concentrates



# How do I know my horse has it?

- EMS horses tend to show the following signs:
  - Obesity
  - Regional adiposity
    - Cresty neck, fat deposits around the tailhead, sheath and above the eyes
  - Laminitis
    - Historical or current
- Veterinarians diagnose EMS by performing a physical exam on the horse and collecting blood samples to look at the horse's glucose and insulin levels



[http://special.equisearch.com/blog/horsehealth/uploaded\\_images/0527ILPH-pony-laminitis-lr-rgb-730888.jpg](http://special.equisearch.com/blog/horsehealth/uploaded_images/0527ILPH-pony-laminitis-lr-rgb-730888.jpg)  
<http://www.alexbrolo.com/johnthetvet/images/ems1.gif>  
[http://www.thehorse.com/images/content/cushings/ecc\\_eyes\\_small.jpg](http://www.thehorse.com/images/content/cushings/ecc_eyes_small.jpg)

# How is it treated?

- Treatment of EMS includes:
  - Inducing weight loss in obese horses
    - Exercise and diet (must be low in non-structural carbohydrates and energy)
  - Treating laminitis as per your veterinarian's instructions, and avoiding dietary triggers to prevent future occurrences
  - Using levothyroxine to promote weight loss and improve insulin sensitivity



# What can I do to prevent EMS?

- Obese horses should have their weight managed
  - Exercise
  - Diet change
    - Hay should be tested (and may need to be soaked to reduce non-structural carbohydrates)
    - Avoid feeding concentrates
    - Turnout on grass should be reduced to only a few hours/day or overnight
    - Outfit the horse or pony with a grazing muzzle



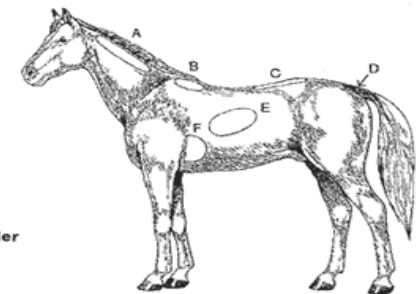
# How do I know if my horse is overweight?

- Many of our equine friends are “well-fed”
- Body condition scoring is a very helpful tool to identify overweight horses and ponies

HENNEKE SYSTEM						
CONDITION	NECK	WITHERS	LOIN	TAILHEAD	RIBS	SHOULDER
<b>1 POOR</b>	Bone structure easily noticeable Animal extremely emaciated; no fatty tissue can be felt	Bone structure easily noticeable	Spinous processes project prominently	Tailhead (pinbones) and hook bones projecting prominently	Ribs projecting prominently	Bone structure easily noticeable
<b>2 VERY THIN</b>	Faintly discernible Animal emaciated	Faintly discernible	Slight fat covering over-base of spinous processes. Transverse processes of lumbar vertebrae feel rounded. Spinous processes are prominent	Tailhead prominent	Ribs prominent	Faintly discernible
<b>3 THIN</b>	Neck accentuated	Withers accentuated	Fat buildup halfway on spinous processes but easily discernible. Transverse processes cannot be felt	Tailhead prominent but individual vertebrae cannot be visually identified. Hook bones appear rounded, but are still easily discernible. Pin bones not distinguishable	Slight fat cover over ribs. Ribs easily discernible	Shoulder accentuated
<b>4 Moderately THIN</b>	Neck not obviously thin	Withers not obviously thin	Negative crease along back	Prominence depends on conformation, fat can be felt. Hook bones not discernible	Faint outline discernible	Shoulder not obviously thin
<b>5 MODERATE</b>	Neck blends smoothly into body	Withers rounded over spinous processes	Back level	Fat around tailhead beginning to feel spongy	Ribs cannot be visually distinguished but can be easily felt	Shoulder blends smoothly into body
<b>6 Moderately FLESHY</b>	Fat beginning to be deposited	Fat beginning to be deposited	May have slight positive crease down back	Fat around tailhead feels soft	Fat over ribs feels spongy	Fat beginning to be deposited
<b>7 FLESHY</b>	Fat deposited along neck	Fat deposited along withers	May have positive crease down back	Fat around tailhead is soft	Individual ribs can be felt, but noticeable filling between ribs with fat	Fat deposited behind shoulder
<b>8 FAT</b>	Noticeable thickening of neck Fat deposited along inner buttocks	Area along withers filled with fat	Positive crease down back	Tailhead fat very soft	Difficult to feel ribs	Area behind shoulder filled in flush with body
<b>9 Extremely FAT</b>	Bulging fat	Bulging fat	Obvious positive crease down back	Building fat around tailhead	Patchy fat appearing over ribs	Bulging fat

**Henneke System of Body Condition**

- A. Along the neck**
  - B. Along the withers**
  - C. Loin/Crease down the back**
  - D. Tailhead**
  - E. Ribs**
  - F. Behind the shoulder**
- Add scores and divide by six.**



# Equine Cushing's Disease

---



# What is it?

---

- Equine Cushing's Disease is also known as Pars Pituitary Intermedia Dysfunction (PPID)
- It is caused by a tumour called an adenoma located in the pars intermedia of the pituitary gland (part of the horse's brain)
- PPID occurs more commonly in pony breeds and in horses and ponies that are 10 years or older (usually 20+ years)

# How do I know my horse has it?

- Horses with PPID tend to show the following signs:
  - Hirsutism (long haircoat) and abnormal shedding
  - Excessive drinking and urination
  - Laminitis
  - Lethargy, loss of muscle mass, frequent infections...
- Veterinarians diagnose a horse/pony with Cushing's disease by doing a physical exam and confirm the diagnosis by performing blood work
  - Because of seasonal influences, it is best not to do the blood work in the fall



<http://americashorstdaily.com/wp-content/uploads/cushings.jpg>



<http://www.horsemanmagazine.com/wp-content/uploads/2008/10/cushings-disease-horses.jpg>

# How is it treated?

- The treatment of choice is a medication called pergolide
- Other management considerations include:
  - Body clipping the horse/pony in the summer if needed
  - Treating laminitis or infections (hoof abscesses, non-healing wounds) as per your veterinarian's instructions




# What can I do to prevent it?

- Equine Cushing's Disease is not a preventable condition, and is fairly common in older horses and ponies
- Managing the condition optimizes the quality of life for our older horse and pony friends



# Bottom line

- With nice weather and green grass fast approaching we need to be careful when turning out our equine friends, particularly the pudgy ones 😊
- If you suspect your horse or pony has Equine Metabolic Syndrome or Equine Cushing's Disease they should be examined by your veterinarian, so that treatment can be started promptly





- Questions?
- Thanks for your attention 😊
- I can't wait to work with you and your horses!

